

Orthotopic liver transplantation for patients with Klatskin tumor

Shu-Sen Zheng, Qian-Feng Shi, Ting-Bo Liang, Jian Wu, Wei-Lin Wang, Yan Shen and Min Zhang

Hangzhou, China

BACKGROUND: It is not certain whether Klatskin tumor should be a routine indication for orthotopic liver transplantation (OLT). This study was to summarize the indication and value of orthotopic liver transplantation for patients with Klatskin tumor.

METHODS: Forty patients with Klatskin tumors including 5 patients who had had liver transplantation (LTx) and 35 patients who had not undergone LTx (WLTx) from January 1992 to December 2003 were analyzed retrospectively. Their TNM stages were comparable in both groups. In the LTx group, 4 patients had Klatskin tumor including recurrent tumor after resection (1), and 1 cancerization from Carolis disease. Biliary duct anastomosis was made by Roux-en-Y choledochojejunostomy in 2, and end-to-end choledochocholedochostomy (C-C) in 3.

RESULTS: In the LTx group, the total resection rate and radical resection rate were both 100%. Four patients have been surviving for 48, 38, 21 and 5 months, respectively, except one died from bile leakage at day 40 after transplantation. All 4 survivors enjoyed good life without tumors at local and distant sites, even though 2 of these patients developed biliary stricture, which was soon resolved by radiological intervention. The 1-, 3-year survival rates were both 80% in this group. The total resection rate and radical resection rate in the WLTx group were 63.0% (17/27) and 40.7% (11/27) and, the 1-, 3-, 5-year survival rates were 32.2%, 8.0%, 0%, respectively. There were significant differences between the two groups in radical resection rates and survival rates ($P=0.016$).

CONCLUSIONS: OLT is a good choice for patients with unresectable Klatskin tumor by routine modalities. The prognosis of patients undergoing OLT is encouraging.

(*Hepatobiliary Pancreat Dis Int* 2005; 4: 28-31)

Author Affiliations: Department of Hepatobiliary and Pancreatic Surgery, First Affiliated Hospital, Zhejiang University School of Medicine, Hangzhou 310003, China (Zheng SS, Shi QF, Liang TB, Wu J, Wang WL, Shen Y and Zhang M)

Corresponding Author: Shu-Sen Zheng, MD, PhD, Department of Hepatobiliary and Pancreatic Surgery, First Affiliated Hospital, Zhejiang University School of Medicine, Hangzhou 310003, China (Tel: 86-571-87236567; Fax: 86-571-87236678; Email: zhengss@mail.hz.zj.cn, zssreview@yahoo.com.cn)

© 2005, Hepatobiliary Pancreat Dis Int. All rights reserved.

KEY WORDS: Klatskin tumor; orthotopic liver transplantation; prognosis

Introduction

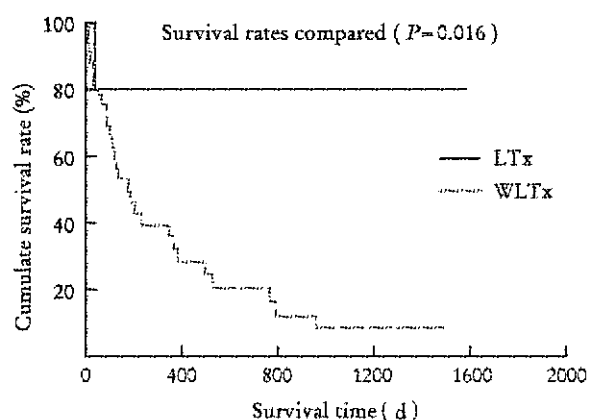
Cases of Klatskin tumor or hilar cholangiocarcinoma account for about 60%-75% of cases of extrahepatic duct carcinoma.^[1] It is a trouble of clinical surgery because of its low resection rate and poor prognosis.^[2] By radical resection the patients may have a longer survival,^[3] but the rate of radical resection for the tumor is only about 30%,^[4] because it is situated in the hilar and involves easily both sides of the portal vein, hepatic artery and secondary biliary tract. Orthotopic liver transplantation (OLT) could resect the tumor and the involved bile duct completely, which is the first choice for radical resection of Klatskin tumor theoretically.^[5] There is a controversy over the value of OLT for the patient with Klatskin tumor,^[6] but it is rarely reported in China. Since 1992 we have accomplished 240 cases of OLT, in whom 5 recipients were patients with Klatskin tumor.

Methods

Forty patients with Klatskin tumors including 5 patients who had undergone liver transplantation (LTx) and 35 who had not had LTx (WLTx) from January 1992 to December 2003 were analyzed retrospectively. The clinical data of the 5 patients were shown in Table. In the LTx group consisted of 4 patients with Klatskin tumor including recurrent tumor after resection (1 patient), and 1 patient with cancerization from Carolis disease. The 5 patients were in IV_A stage (TNM stage, UICC1997) and their liver function was graded Child C before operation. Bismuth-Corlette typing showed that 2 patients were in IIIa and 3 in IV. Blumgart T Staging revealed 1 was in T₂, 2 in T₃ and 2 in T₄. Exploration revealed that all tumors could not be radically resected by routine modalities. Classical OLT was performed and the bile duct was reconstructed by a Roux-en-Y chole-

Table. The clinical data of 5 patients with Klatskin tumor in the LTx group

Variables	1	2	3	4	5
Sex	Male	Male	Male	Female	Female
Age(years)	42	52	47	61	64
Compounding disease	-	Carolis disease	-	Posthepatic cirrhosis	Cholangiocarcinoma recurrence
Tumor size(cm)	3×2	fill	2×2	4×3.5	1.5×1.5
Invaded structure	Common hepatic duct, right secondary bile duct and metastasis in right liver	Common hepatic duct and both sides of secondary bile duct	Common hepatic duct and both sides of secondary bile duct	Common hepatic duct and both sides of secondary bile duct	Common hepatic duct and right secondary bile duct
Bismuth type	IIIa	IV	IV	IV	IIIa
TNM stage	T ₃ N ₀ M ₀ ,IV _A	T ₃ N ₀ M ₀ ,IV _A	T ₃ N ₁ M ₀ ,IV _A	T ₃ N ₂ M ₀ ,IV _A	T ₃ N ₁ M ₀ ,IV _A
Blumgart stage	T ₃	T ₄	T ₄	T ₃	T ₂
Liver function (Child)	C	C	C	C	C
Pathology	Adenocarcinoma medium differentiation	Carolis disease cancerization	Adenocarcinoma medium differentiation	Adenocarcinoma low differentiation	Adenocarcinoma medium differentiation
PTNM stage	pT ₃ N ₀ M ₀	pT ₃ N ₀ M ₀	pT ₃ N ₁ M ₀	pT ₃ N ₁ M ₀	pT ₃ N ₁ M ₀
Bile duct reconstructed	C-C	C-J	C-C	C-C	C-J
Complication after operation	Acute rejection biliary stricture infection	Acute rejection infection	Biliary stricture	Thrombus in hepatic artery;bile leakage;infection in abdominal	Infection
Final/survival time (month)	Survival/48	Survival /38	Survival/21	Dead/1.3	Survival /5


Fig. The survival curve of the LTx and WLTx groups.

choledochojunostomy in 2 patients, and end-to-end choledochocholedochostomy (C-C) in 3 (2 with T-tube drainage and 1 without). All patients received prednisolone and either cyclosporin and azathioprine or tacrolimus as immunosuppressive agents after transplantation.

To make the two groups comparable, 35 patients in the same period and in the same IV_A stage were chosen for WLTx. Bismuth-Corlette typing showed type I 3 patients, type II 7, type IIIa 3, type IIIb 7, type IV 15; and Blumgart T staging revealed: stage T₁ 8 patients, T₂ 5, T₃ 7, and T₄ 15. Twenty-seven patients underwent surgery including resection (17 patients),

[radical resection (11), and palliative resection (6)], 3 common bile duct resection and choledochojunostomy, 5 square lobe resection and choledochojunostomy, 7 left hemihepatectomy and choledochojunostomy, and 2 hepato-pancreatico-duodenostomy. Ten patients were subjected to palliative intra-drainage (3) or extra-drainage (5) or biopsy (2). Eight patients were given traditional Chinese medicine or immunotherapy. The survival rate of the two groups were calculated by the Kaplan-Meier method and the log-rank test with SPSS10.0 statistical software of the adjustment for the types of operation.

Results

In the LTx group, the total resection rate and radical resection rate were both 100%. The operative modality was 0; but 80% of the patients suffered from pulmonary or abdominal infection, and they were recovered after antibiotic treatment. Acute rejection in 2 patients were controlled by steroid stroke therapy. Four patients have been surviving for 48, 38, 21 and 5 months respectively, except one who died from bile leakage at day 40 after transplantation. The 4 survivors have a good quality of life without tumor recurrence or metastasis. The median survival was 38 months (1 month-48 months), and the overall 1-, 3-year survival rates were both 80%. Even though biliary stricture developed in 2 of the 4 pa-

tients, it was resolved by radiological intervention.

The total resection rate and radical resection rate in the WLTX group were 63.0% (17/27) and 40.7% (11/27), respectively. The operative modality was 3.7% (1/27), and in 11.1% patients (3/27) developed bile leakage, which was the commonest complication after operation. The median survival was 5.8 months (0.1 month–49.2 months), and the overall 1-, 3-, 5-year survival rates were 32.2%, 8.0%, 0, respectively, which were lower than those of the LTx group ($P = 0.016$) (Fig).

Discussion

In recent years the incidence of Klatskin tumor has been increasing, its resection rate and long-term survival are still not satisfactory despite surgical techniques have been greatly improved.^[7,8] The total resection rate and radical resection rate of 83 patients with Klatskin tumor were 70.9% (41/58) and 53.4% (31/58) in recent 10 years at our hospital. The overall 1-, 3-, 5-year survival rates and those of the radical resection group were 43.8%, 20.6%, 6.4% and 78.6%, 60.2%, 24.1%, respectively, indicating that radical resection is an efficient approach to improving long-term survival of patients with Klatskin tumor. But the tumor is located in the porta hepatis hilar, invading both sides of the tri-canal structure and resulting in hepatic lobe atrophy, which make local radical resection difficult.^[9] Extensive radical resection including Klatskin tumor resection, nodal clearance of hepatoduodenal ligament, resection of hepatic lobe with the caudal lobe and resection of the portal vein or hepatic artery was advocated in order to increase the rate of radical resection.^[10] But it is often associated with many shortcomings such as excessive operative damage, more postoperative complications, and failure to carry out radical resection in all patients. The long-term survival of patients can not be attained.^[11] Because of the biological characteristics of Klatskin tumor and the specialty or predominance of OLT, OLT is considered undoubtedly the thorough radical resection. Nevertheless, the value of OLT for patients with Klatskin tumor is still controversial. After all, the high risk of tumor recurrence under long-term immunosuppression, the limited availability of donor organs and the excellent results of liver transplantation in non-malignant diseases do not justify this procedure at present.^[12] The radical resection rate, however, could be increased by OLT, thus offering a chance for the long-term survival of the patients.^[13] In this study, 5 patients of the LTx group could not undergo radical resection with other modality. Lee et al^[14] reported 15 patients with Klatskin tumor who underwent OLT combined with pancreatoduodenectomy with a radical resection rate of 93%, which was remarkably higher than that of the patients who underwent hepatic

resection ($P < 0.05$). Reviewing Spanish experience in OLT for 36 patients with Klatskin tumor in 13 years, Robles et al^[15] reported the actuarial survival rate at 1, 3, and 5 years after OLT was 82%, 53%, and 30%, respectively. Iwatsuki et al^[16] reported 72 patients who had had hepatic resection (34 patients) or transplantation (38). The survival rates of these patients at 1, 3, and 5 years after hepatic resection were 74%, 34%, and 9%, respectively, and those after transplantation were 60%, 32%, and 25%, respectively. The survival rates were not significantly different between the hepatic resection and transplantation groups ($P > 0.05$). Our experience have shown that recipients could get a long-term non-tumor survival as well as a good life quality. In this study, the survival rate of the LTx group was remarkably higher than that in the WLTX group and also better than that in patients undergoing routine radical resection. These demonstrate the superiority of OLT for patients with Klatskin tumor. Hence OLT is a good choice for patients with advanced-stage unresectable Klatskin tumor by routine modalities.

Pichlmayr et al^[17] suggested the indications of OLT for patients with Klatskin tumor; (1) tumors of UICC II stage that could not be resected by exploration; (2) Tumors for R₀ resection (no residual tumor) that could not be completed because of tumor focus centered, with R₁ (microscopic residual tumor) or R₂ resection (gross residual tumor) possible; (3) recurrent tumors after resection. The bile duct could be reconstructed by a Roux-en-Y choledochojejunostomy or end-to-end choledochocholedochostomy (C-C). As to the latter, it must be assured that the distal wedge of the recipient bile duct was negative pathologically. In this study, the bile ducts of 3 recipients in the LTx group were reconstructed by end-to-end choledochocholedochostomy (C-C), and no local tumor recurrence was observed. But 2 patients with a long-survival developed biliary stricture, which may be due to the clearance of the hepatoduodenal ligament. The stricture was resolved by radiological intervention.^[18,19] The necessity of radiochemotherapy preoperation or postoperation was not confirmed.^[20]

Competing interest

No benefits in any form have been received or will be received from a commercial party related directly or indirectly to the subject of this article.

References

- Jarnagin WR, Shoup M. Surgical management of cholangiocarcinoma. *Semin Liver Dis* 2004;24:189-99.
- Yi B, Zhang BH, Zhang YJ, Jiang XQ, Zhang BH, Yu WL,

- et al. Surgical procedure and prognosis of hilar cholangiocarcinoma. *Hepatobiliary Pancreat Dis Int* 2004;3:453-457.
- 3 Becker T, Lehner F, Bektas H, Meyer A, Luck R, Nashan B, et al. Surgical treatment for hilar cholangiocarcinoma (Klatskin's tumor). *Zentralbl Chir* 2003;128:928-935.
 - 4 Neuhaus P, Jonas S, Bechstein WO, Lohmann R, Radke C, Kling N, et al. Extended resections for hilar cholangiocarcinoma. *Ann Surg* 1999;230:808.
 - 5 Heimbach JK, Gores GJ, Haddock MG, Alberts SR, Nyberg SL, Ishitani MB, et al. Liver transplantation for unresectable perihilar cholangiocarcinoma. *Semin Liver Dis* 2004;4:201-207.
 - 6 Boberg KM, Schrupf E. Diagnosis and treatment of cholangiocarcinoma. *Curr Gastroenterol Rep* 2004;6:52-59.
 - 7 He ZP, Hou WL, Bie P, Dong JH, Wang SG, Han BL, et al. Etiology and surgical treatment of hilar bile duct stricture. *Hepatobiliary Pancreat Dis Int* 2003;4:587-593.
 - 8 Kondo S, Hirano S, Ambo Y, Tanaka E, Okushiba S, Morikawa T, et al. Forty consecutive resections of hilar cholangiocarcinoma with no postoperative mortality and no positive ductal margins; results of a prospective study. *Ann Surg* 2004;240:95-101.
 - 9 Acalovschi M. Cholangiocarcinoma: risk factors, diagnosis and management. *Rom J Intern Med* 2004;42:41-58.
 - 10 Guo ZJ, Li Q, He K. Diagnosis and treatment of hepatic cholangiocarcinoma; report of 52 cases. *Hepatobiliary Pancreat Dis Int* 2003;1:62-65.
 - 11 Endo I, Shimada H. Present situation of and prospects for standardization of surgery for biliary tract cancer. *Nippon Geka Gakkai Zasshi* 2003;104:404-411.
 - 12 Becker T, Lehner F, Bektas H, Meyer A, Luck R, Nashan B, et al. Surgical treatment for hilar cholangiocarcinoma (Klatskin-tumor). *Zentralbl Chir* 2003;128:928-935.
 - 13 Robles R, Figueras J, Turrion VS, Margarit C, Moya A, Varo E, et al. Spanish experience in liver transplantation for hilar and peripheral cholangiocarcinoma. *Ann Surg* 2004;239:265-271.
 - 14 Lee SG, Lee YJ, Park KM, Hwang S, Min PC. One hundred and eleven liver resections for hilar bile duct cancer. *J-Hepatobiliary-Pancreat-Surg* 2000;7:135-141.
 - 15 Robles R, Figueras J, Turrion VS, Margarit C, Moya A, Varo E, et al. Liver transplantation for hilar cholangiocarcinoma: Spanish experience. *Transplant Proc* 2003;35:1821-1822.
 - 16 Iwatsuki S, Todo S, Marsh JW, Madariaga JR, Lee RG, Dvorchik I, et al. Treatment of hilar cholangiocarcinoma (Klatskin tumors) with hepatic resection or transplantation. *J Am Coll Surg* 1998;187:358-364.
 - 17 Pichlmayr R, Weimann A, Klempnauer J, Oldhafer KJ, Maschek H, Tusch G, et al. Surgical treatment in proximal bile duct cancer. A single center experience. *Ann Surg* 1996;224:628-638.
 - 18 Zhou PH, Yao LQ, Zhang YQ, Gao WD, He GJ, Xu MD, et al. Endoscopic biliary drainage for biliary obstruction. *Hepatobiliary Pancreat Dis Int* 2003;4:598-601.
 - 19 Tan JW, Jiang Y, Yao HX, Lu LZ, Zhang SG. Early prevention and treatment of biliary tract complications after orthotopic liver transplantation. *Hepatobiliary Pancreat Dis Int* 2003;1:48-53.
 - 20 Sudan D, DeRoover A, Chinnakotla S, Fox I, Shaw B Jr, McCashland T, et al. Radiochemotherapy and transplantation allow long-term survival for nonresectable hilar cholangiocarcinoma. *Am J Transplant* 2002;2:774-779.

Received April 5, 2004

Accepted after revision December 18, 2004